Research article

V.K.Syrtsov
I.N.Maslova

Zaporizhzhya State Medical University

UDC: 611.316.013-018:[611.013:616-097]:599.323.4

DISTRIBUTION FEATURES OF THE RATS' MAJOR SALIVARY GLANDS CELLS GLYCOPROTEINS DURING EARLY POSTNATAL PERIOD AFTER ANTENATAL ANTIGEN ACTION

This study was done within the research «Lectinhistochemical characteristics of morphogenesis of the organs and tissues in early postnatal period in norm and experiment» (state registration number 0109U003986).

ABSTRACT. Background. Nowadays, in the diseases' structure, according to literature data, one of the leading place take pathological condition connecting with the salivary glands' inflammatory and dystrophic disorders. The problem of etiology and pathogenic not enough studied and demanded intent attention of researchers. **Objective.** The purpose was to determine the features of glycoproteins' distribution in the structures of rats' major salivary glands in early postnatal period after intrauterine antigen action. **Methods.** The object of the research was 224 salivary glands of white laboratory rats. Due to impossible quality materials' taking in the early periods of postnatal life parotid and sublingual salivary glands, the investigation done at the gl. submaxillaris. The histochemical exposure and differentiation of carbohydrate compounds conducted by means of PAS-staining technic. For fermentative control used diastase. The results of histochemical exposure of glycoproteins stain were done by semi-quantitative. **Results.** In newborn animals receiving antigen in the antenatal period, in the cells' cytoplasm indicate the accumulation' increase of PAS-positive compounds retained until the 14th and offset at the 45th day of postnatal life. The detected changes in the major salivary glands cells' are the basis for the development of inflammatory and dystrophic processes and can lead to the functional violations formation' hereinafter. **Conclusion.** Our findings indicate that at the background of intrauterine antigen action, the glycoproteins' accumulation intensity in parenchymal and stromal cells' cytoplasm of the major salivary glands is decrease, but glycogen content is increase compared with intact animals group. Furthermore, we detected cells' secretory activity reduction from 1st to 14th day of postnatal life with increase glycogen' accumulation in the cells' cytoplasm. That revealed changes offset at the 45th day after birth in all animals group.

Key words: major salivary glands, parenchymal cells, stromal cells, intrauterine antigenic action, glycosaminoglycans, the rats.

© V.K.Syrtsov, I.N.Maslova, 2014

✉ **axios.ua@gmail.com**

Received: 04.06.2014
Accepted: 22.06.2014

Citation:
Syrtsov VK, Maslova IN. Distribution features of the rats' major salivary glands cells glycoproteins during early postnatal period after antenatal antigen action. Morphologia. 2014;8(2):56-60.

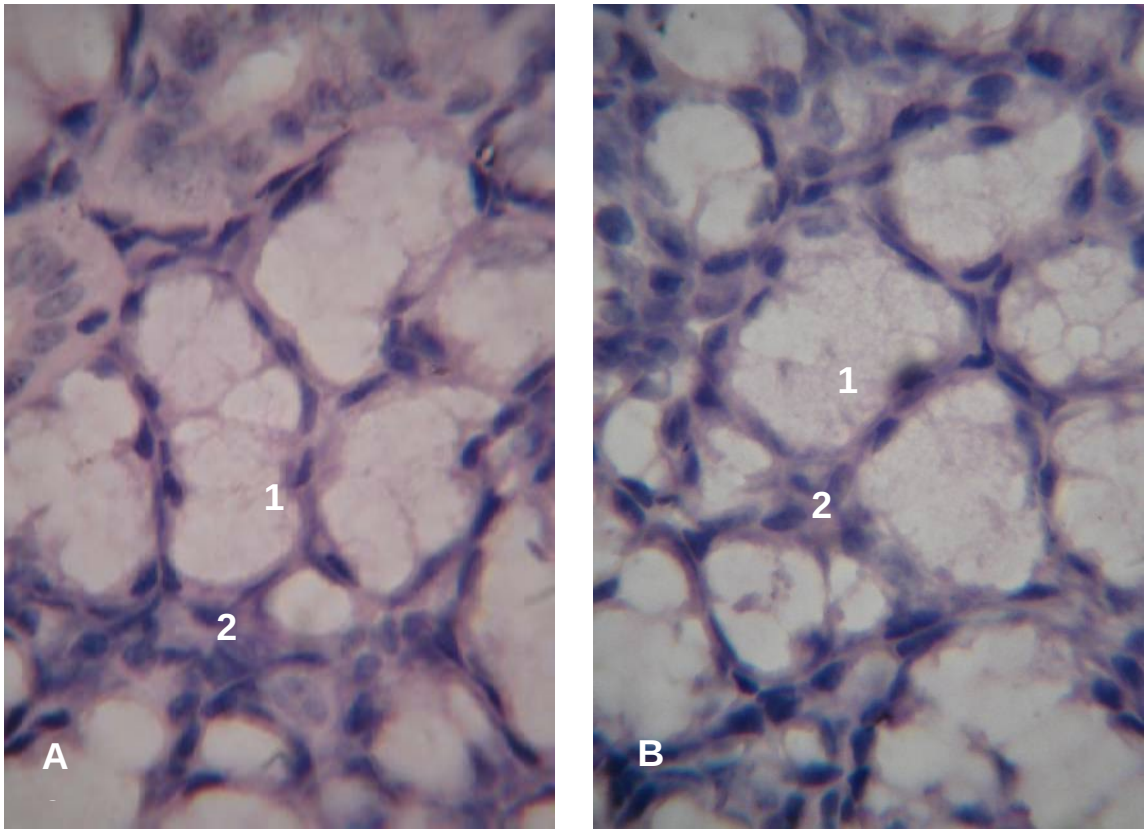

Fig. 1. Representative sections from rats' submandibular glands of experimental group, the 1 st day after birth (a – PAS reaction; b – PAS reaction with Diastase; Nuclei Coloration – Ehrlich's Hematoxylin; Original Magnification ×1000) 1 – parenchymal cells; 2 – stromal cells.

References:

1. Jingxiu X, Long S, Kishore M. Temporal histological changes in lacrimal and major salivary glands in mouse models of Sjogren's syndrome. BMC Oral Health 2013;13:51 doi: 10.1186/1472-6831-13-51.

2. Voloshyn NA. [Lymphocyte – of factor morphogenesis]. Zaporozhskiy medicinskiy zhurnal. 2005;5:122. Russian.

3. Voloshyn NA, Grigor'eva EA. [The experimental model of undifferentiated connective tissue syndrome' formation]. Patologiya. 2009;6(1):39-42. Ukrainian.

4. Burega YuO. [Distribution features of glycoproteins in the structures of periodontium and mucous membrane of rats' gums in a norm and after intrauterine antigen action]. Actualni pitannya pharmacevtichnoi i medichnoi nauki ta practiki. 2013;2 (dodatok):6. Ukrainian.

5. Voloshyn MA, Burega YuA. Distribution features of glycoproteins in the structures of periodontium and mucous membrane of rats' gums in a norm and after intrauterine antigen action. Ukrainskiy medichniy almanah. 2013;16(3):40-3.

6. Yamaoka M, Matsuura T, Doto R, Hotomi H. P-glycoprotein expression in human major and minor salivary glands. Arch Oral Biol. 2001 Jun;46(6):521-7.