R.V.Antonyuk [1,2]
A.D.Lutsyk [1]

[1] Danylo Halytsky Lviv National Medical University
[2] Dubno Central Regional Hospital, Rivne region, Ukraine

Key words:
lectin histochemistry, intestine, vertebrates, carbohydrate determinants.

UDC [611.018+616.345-006]+547.96

LECTIN HISTOCHEMISTRY OF INTESTINAL CARBOHYDRATE DETERMINANTS IN REPRESENTATIVES OF DIFFERENT CLASSES OF VERTEBRATES

The study was performed as a part of research work "Lectin histochemistry of normal and neoplastic large intestine" (state registration number 0113U000207).

ABSTRACT. Background. Glycoproteins (including mucin) of vertebrate's intestine play an important role in its protection against chemical and mechanical damage and bacterial attacks. Their diversity was described by many authors, but understanding of their chemical structure remains far from complete. These data can be extended by methods of lectin histochemistry. **Objective.** To investigate the rearrangement of intestinal carbohydrate determinants in the context of vertebrate evolution. **Methods**. Distal and proximal segments of small and large intestines of humans (*Homo sapiens*), laboratory (Wistar) rat (*Rattus norvegicus f. Domesticus*), rock pigeon (*Columba livia*), smooth snake (*Coronella austriaca*), common frog (*Rana temporaria*), common carp (*Cyprinus carpio*) that belong to different classes of vertebrates were taken for the experiment. Nine lectins with different carbohydrate specificities: wheat germ (WGA), potato (STA), elderberry bark (SNA), golden rain bark (LABA), locust bark (RPBA), roe carp (CCRA), Phaseolus vulgaris erytroagglutinin (PHA-E), peanut (PNA) and jack fruit (AIA) – were included into the panel. **Results.** Differences in lectin staining between small and large intestine were more pronounced in higher (human, rat) than in lower (frog, carp) vertebrates. Lectin receptors were more diverse in frog intestine in comparison with carp. Lectin interaction with mucin secretory granules of smooth snake revealed lack of N-acetyl-D-glucosamine residues and abundance of N-acetyl-D-galactosamine determinants. **Conclusion**. Intestines of all studied vertebrate species demonstrate high content of secretory mucins that exposed terminal acidic carbohydrates including sialic acid. The diversity and differences in the structure of glycans of the digestive tract of vertebrates is apparently determined by several factors – diet, environmental and living conditions, intestinal microbiota interactions etc.

© R.V.Antonyuk, A.D.Lutsyk, 2015
✉ **antonyukvo@gmail.com**

Received: 22.11.2015
Accepted: 18.12.2015

Citation:
Antonyuk RV, Lutsyk AD. [Lectin histochemistry of intestinal carbohydrate determinants in representatives of different classes of vertebrates]. Morphologia. 2015;9(4):7-20. Ukrainian.

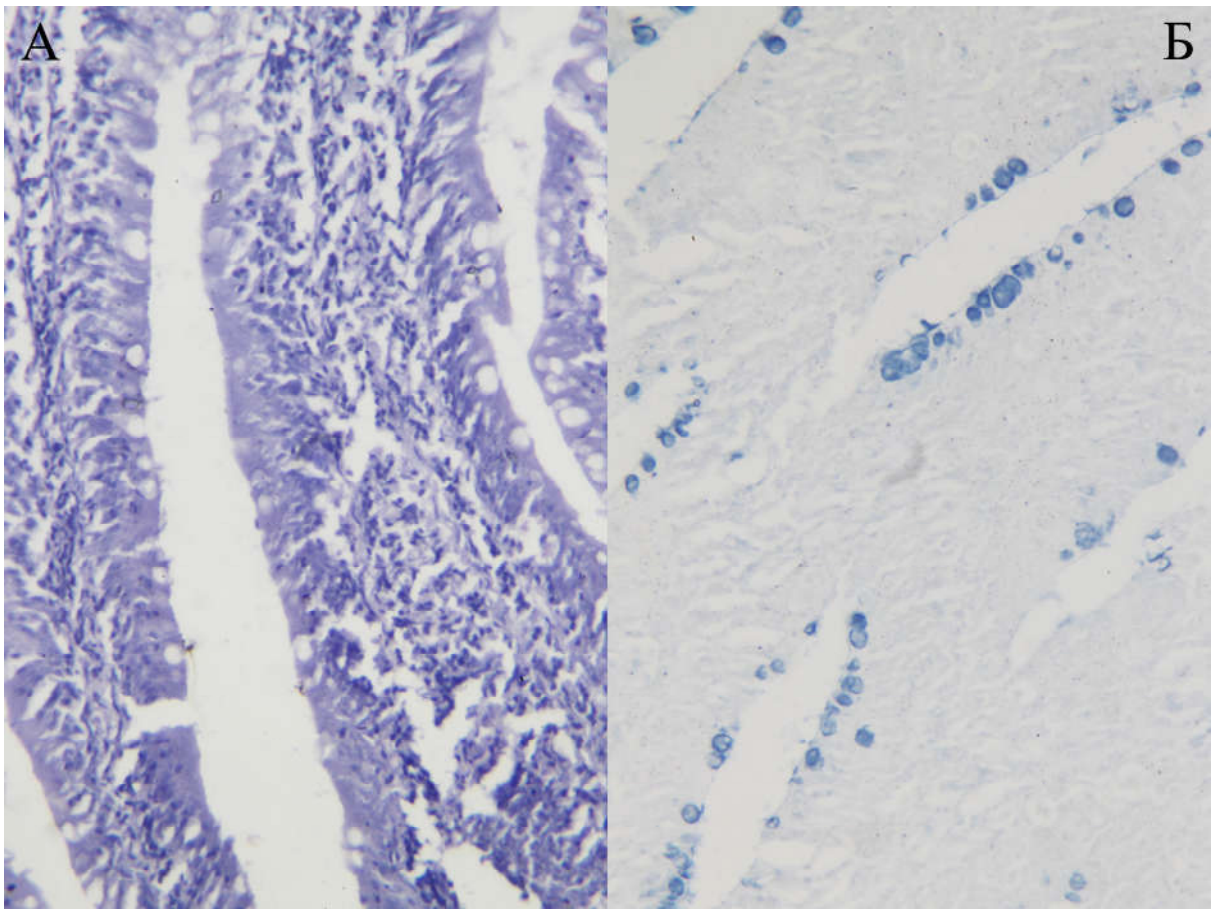

Fig. 1. Common capr small intestine mucosa. A) PAS-reaction + hematoxylin: enterocytes cytoplasm is PAS-positive, nuclei are stained with hematoxylin, secretory granules of goblet cells are not stained; Б) Alcian blue staining: clear visualization of the secretory compartment in goblet cells.

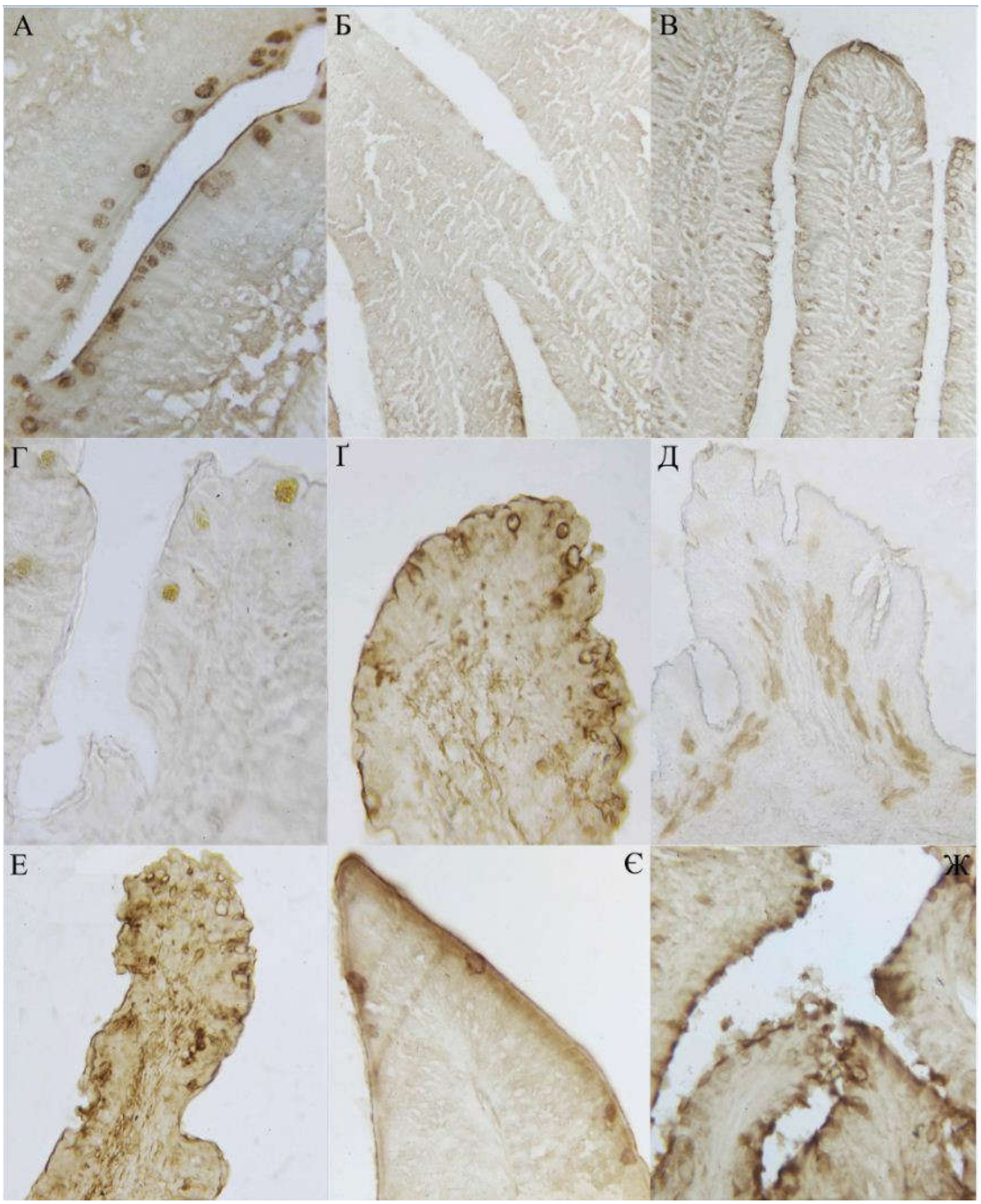

Fig. 2. А) Common carp foregut mucosa, WGA treatment: intense reactivity of the secretory compartments in goblet cells and microvilli of the luminal surface of enterocytes, ×200. Б) Common carp hindgut, RPBA treatment: weak staining of mucin granules, ×100. В) Common carp hindgut, SNA treatment: weak reactivity of the goblet cells secretions and the lumenal surface of enterocytes, ×100. Г) Common frog, small intestine, PHA-E treatment: staining of the secretory granules in individual goblet cells, ×200. Ґ) Common frog, small intestine, WGA treatment: lectin binding to the membranes of secretory compartments and the luminal surface of enterocytes, ×100. Д) Common frog, large intestine, LABA treatment: lectin receptors located under the epithelial lining, probably in the cytoplasm of intestinal glands' cells, ×100. Е) Common frog, large intestine, STA treatment: heterogeneous reactivity of the secretory granules located at varying heights in goblet cells, ×100. Є) Smooth snake, small intestine, AIA treatment: lectin binding to the secretory compatments of goblet cells, glicopolimers of the luminal surface and in the apical division of cytoplasm of villi enterocytes, ×200. Ж) Smooth snake, small intestine, SNA treatment: reactivity of the secretory compartments of goblet cells and the luminal enterocyte plasmalemma, ×100.

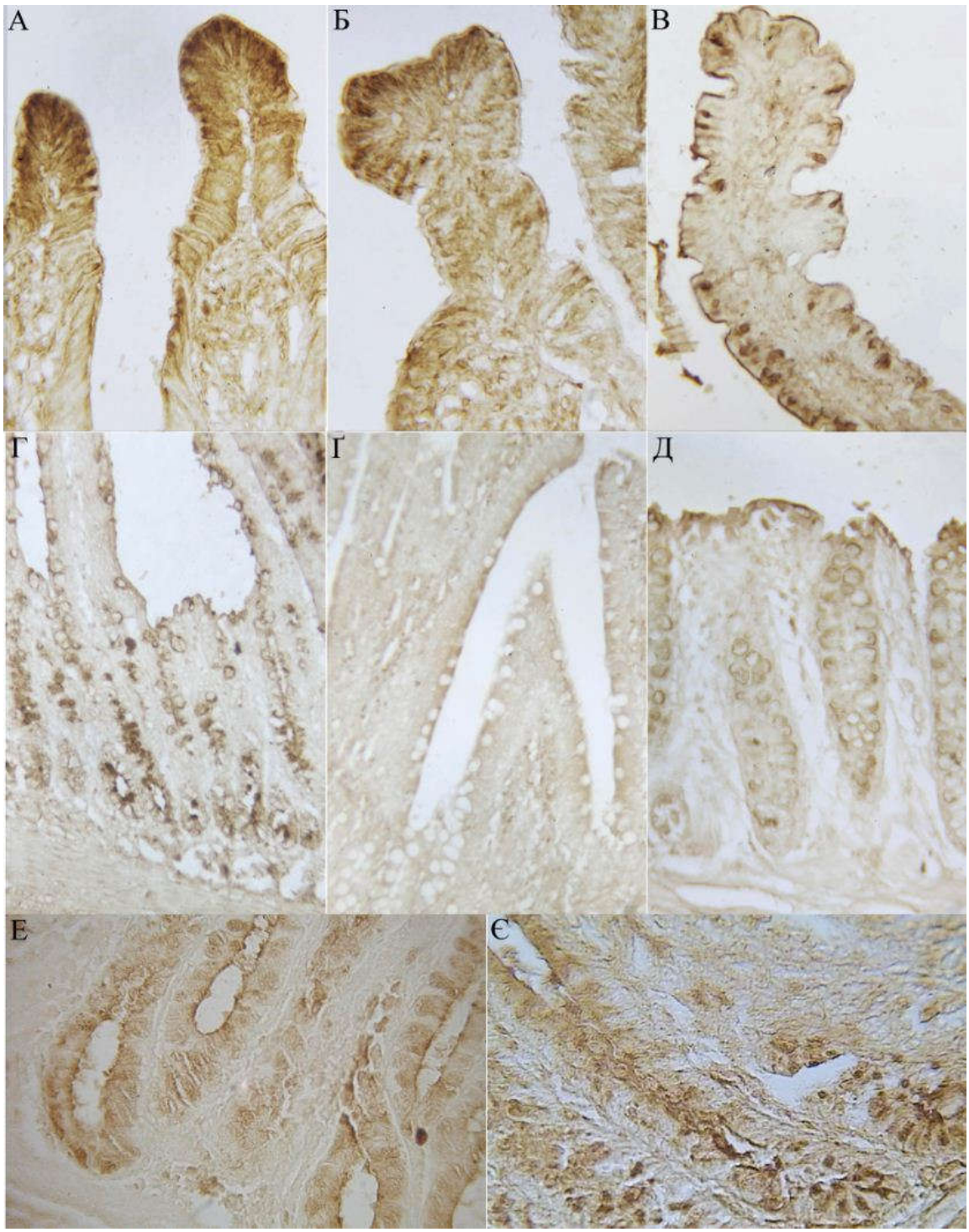

Fig. 3. А) Rock pigeon, small intestine, AIA treatment: staining of the submembranous and apical cytoplasm of enterocytes located on the apices of villi, ×200. Б) Rock pigeon, small intestine, CCRA treatment: lectin receptors located in the supranuclear cytoplasm of columnar cells, ×200. В) Rock pigeon, large intestine, SNA treatment: staining of the secretory granules and the luminal enterocyte plasmalemma, ×100. Г) Rat small intestine, LABA treatment: intense mucin staining in goblet cells, especially in the middle and lower divisions of crypts, ×100. Ґ) Rat small intestine, AIA treatment: weak expression of the receptors in the upper division of columnar cell cytoplasm and in the luminal plasmalemma, ×100. Д) Human large intestine, WGA treatment: staining of the secretory granules of goblet cells and the luminal membrane of cells lining the organ lumen, ×200. Е) Rat large intestine, SNA staining: intense staining of the secterory granules of goblet cells, ×400, similar to the results of WGA treatment (Є).

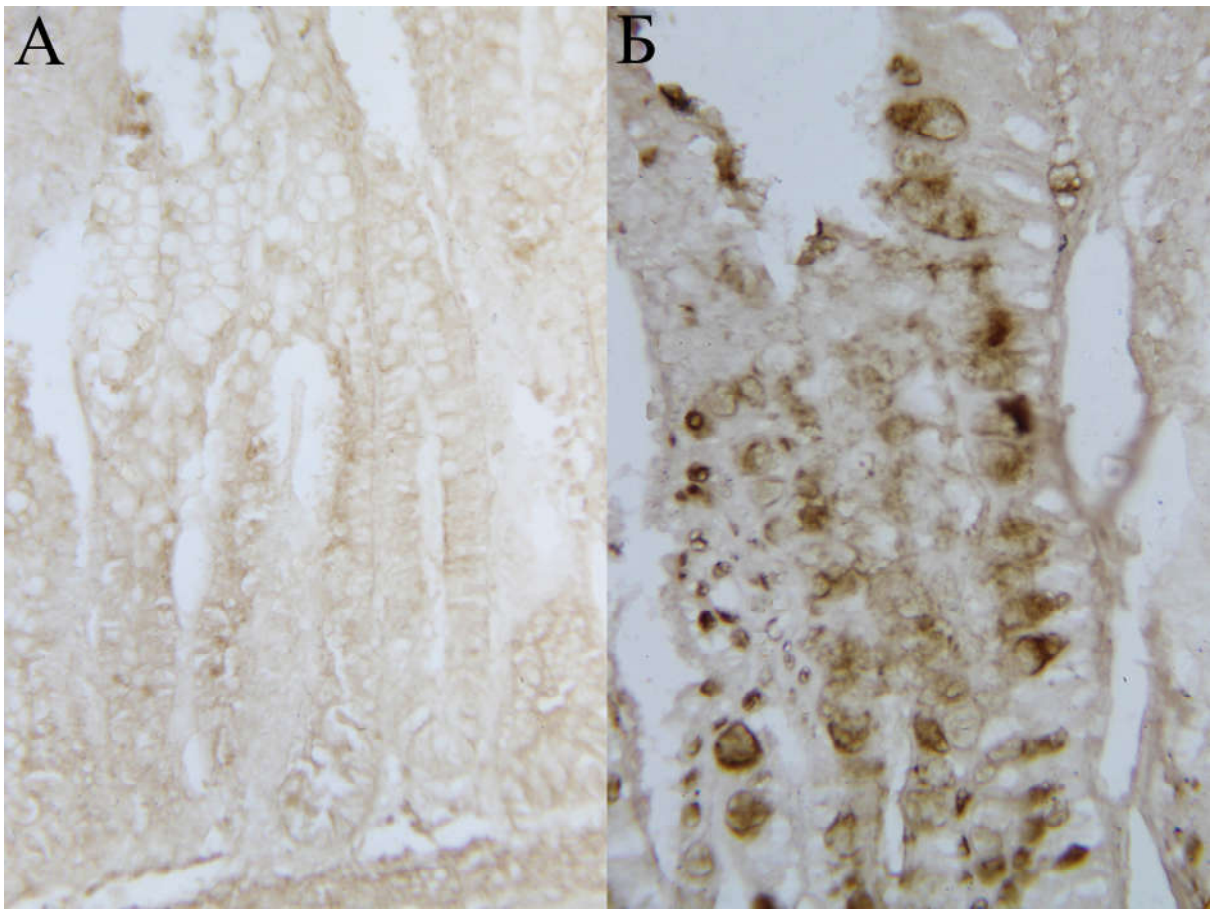

Fig. 4. Rock pigeon, small intestine. А) (PNA treatment) weak staining of cytoplasmic receptors of enterocytes, secretory granules are not stained. (×100). Б) (PNA treatment subsequent to neuraminidase treatment) marked staining of the goblet cells secretory granules (×200).

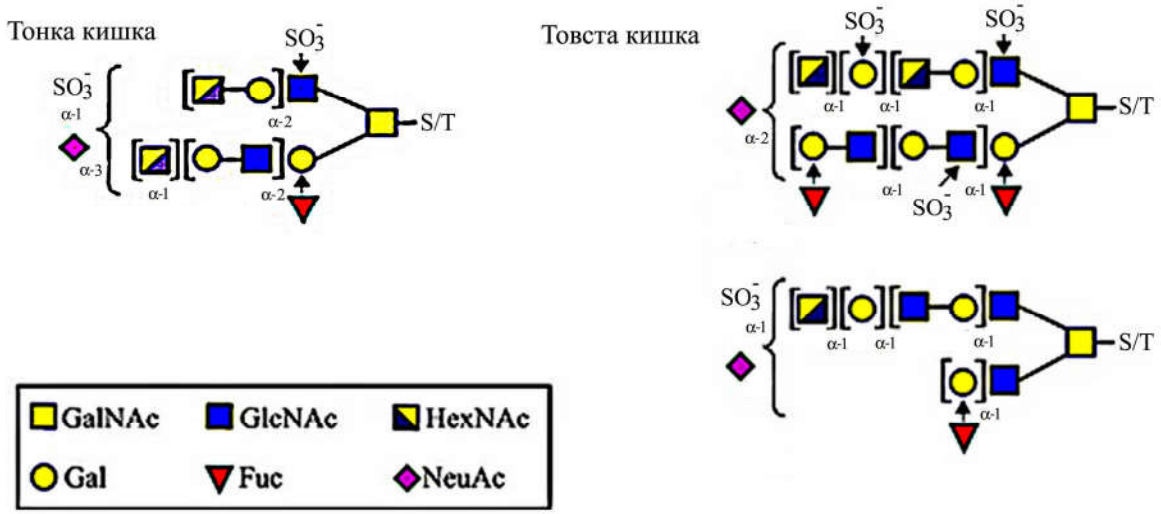

Fig. 5. Variants of carbohydrate determinants in the mammal intestine mucins [23].

References:

1. Narimatsu H. Development of basic tools for glycoscience and their application to cancer diagnosis: A 10-year strategy of the research center for medical glycoscience of AIST. Synthesiology. 2012 Jan; 5(3):190-203.

2. Schultz MJ, Swindall AF, Bellis SL. Regulation of the metastatic cell phenotype by sialylated glycans. Cancer Metastasis Rev. 2012 Dec;31(3-4):501-18. doi: 10.1007/s10555-012-9359-7.

3. Boland CR, Chen YF, Rinderle SJ, Resau JH, Luk GD, Lynch HT, Goldstein IJ. Use of the lectin from Amaranthus caudatus as a histochemical probe of proliferating colonic epithelial cells. Cancer Res. 1991 Jan 15;51(2):657-65.

4. Brinck U, Bosbach R, Korabiowska M, Schauer A, Gabius HJ. Histochemical study of expression of lectin-reactive carbohydrate epitopes and glycoligand-binding sites in normal human appendix vermiformis, colonic mucosa, acute appendicitis and colonic adenoma. Histol Histopathol. 1996 Oct;11(4):919-30.

5. Antonyuk RV, Lutsik OD. [Lectinohystochemical research of colon in humans at normal and at neoplastic process using lectins specific for T antigen and N-acetyllactosamine]. World of Medicine and Biology 2015;(2):73-8. Ukrainian.

6. Coetzee HL, Kotzé SH, Lourens N. Characterization of mucus glycoproteins in the intestinal mucosa of the African elephant (Loxodonta africana) following lectin histochemistry. Onderstepoort J Vet Res. 1995 Sep;62(3):187-92.

7. Suprasert A, Fujioka T, Yamada K. The histochemistry of glycoconjugates in the colonic epithelium of the chicken. Histochemistry. 1987;86(5):491-7.

8. Madrid JF, Ballesta J, Castells MT, Marin JA, Pastor LM. Characterization of glycoconjugates in the intestinal mucosa of vertebrates by means of lectin histochemistry. Acta Histochem Cytochem. 1989; 22:1-14.

9. McGuckin MA, Lindén SK, Sutton P, Florin TH. Mucin dynamics and enteric pathogens. Nat Rev Microbiol. 2011 Apr;9(4):265-78. doi: 10.1038/nrmicro2538.

10. Kim YS, Ho SB. Intestinal goblet cells and mucins in health and disease: recent insights and progress. Curr Gastroenterol Rep. 2010 Oct;12(5):319-30. doi: 10.1007/s11894-010-0131-2.

11. Matsuo K, Ota H, Akamatsu T, Sugiyama A, Katsuyama T. Histochemistry of the surface mucous gel layer of the human colon. Gut. 1997 Jun;40(6):782-9.

12. Larsson JM, Karlsson H, Sjövall H, Hansson GC. A complex, but uniform O-glycosylation of the human MUC2 mucin from colonic biopsies analyzed by nanoLC/MSn. Glycobiology. 2009 Jul;19(7):756-66. doi: 10.1093/glycob/cwp048.

13. Nakane PK, Kawaoi A. Peroxidase-labeled antibody. A new method of conjugation. J Histochem Cytochem. 1974 Dec;22(12):1084-91.

14. Antonyuk VA, Yashchenko AM. [Conjugation of lectins with horseradish peroxidase: optimisation of the method]. Clinical and Laboratory Diagnostic. 1996; 3:51-2. Ukrainian.

15. Lutsyk AD, Detiuk TS, Lutsyk MD. [Lectins in histochemistry]. Lviv: Vyshcha Shkola; 1989. 144 p. Russisan.

16. Antonyuk VO. [Lectins and their resources]. Lviv: Kvart; 2005. 554 p. Ukrainian.

17. Kovtun MF. Comparative anatomy of vertebrates. Kharkiv: Vyshcha Shkola; 2003. Part 2. 272 p. Ukrainian.

18. Mazon AF, Huising MO, Taverne-Thiele AJ, Bastiaans J, Verburg-van Kemenade BM. The first appearance of Rodlet cells in carp (Cyprinus carpio L.) ontogeny and their possible roles during stress and parasite infection. Fish Shellfish Immunol. 2007 Jan-Feb;22(1-2):27-37.

19. Karam SM. Lineage commitment and maturation of epithelial cells in the gut. Front Biosci. 1999 Mar 15;4:D286-98.

20. Lin Yan, Xiao Qiu-Zhou. Dietary glutamine supplementation improves structure and function of intestine of juvenile Jian carp (*Cyprinus carpio var. Jian*). Aquaculture 2006; 256(1-4):389-94.

21. Imagawa T, Hashimoto Y, Kon Y, Sugimura M. Lectin histochemistry as special markers for rodlet cells in carp, *Cyprinus carpio L*. J.Fish Disease 1990; 13(6):537-40. DOI: 10.1111/j.1365-2761.1990.tb00814.x

22. Kingsbury BF. The histological structure of the enteron of *Necturus maculates*. Proc Am Microscop Soc. 1894;16(1):19-64. DOI: 10.2307/3220718.

23. Cummings RD, Pierce JM. Handbook of glycomics. Amsterdam: Academic Press/Elsevier; 2009. 489 p.

24. Neuhaus H, Van der Marel M, Caspari N, Meyer W, Enss ML, Steinhagen D. Biochemical and histochemical study on the intestinal mucosa of the common carp *Cyprinus carpio L*., with special consideration of mucin glycoproteins. J Fish Biol. 2007; 70(5):1523-34. DOI: 10.1111/j.1095-8649.2007.01438.x

25. Yamashita K, Hitoi A, Kobata A. Structural determinants of Phaseolus vulgaris erythroagglutinating lectin for oligosaccharides. J Biol Chem. 1983 Dec 25;258(24):14753-5.

26. Lutsyk AD, Bankston PW. [Heterogeneity of rat cellular subset as detected by lectin-gold probes]. Acta Medica Leopoliensia. 1997;(1-2):70-8. Ukrainian.

27. Sata T, Roth J, Zuber C, Stamm B, Heitz PU. Expression of alpha 2,6-linked sialic acid residues in neoplastic but not in normal human colonic mucosa. A lectin-gold cytochemical study with *Sambucus nigra* and *Maackia amurensis* lectins. Am J Pathol. 1991;139:1435-48.

28. Antonyuk RV, Yashchenko AM, Preima CI. [Possibility of lectins application for drug targeting to carbohydrate determinantes of large intestine]. Prakticheskaia fitoterapiia. 2009;1:24-6. Russian.

29. Rabijns A, Verboven C, Rougé P, Barre A, Van Damme EJ, Peumans WJ, De Ranter CJ. Structure of a legume lectin from the bark of Robinia pseudoacacia and its complex with N-acetylgalactosamine. Proteins. 2001 Sep 1;44(4):470-8.

30. Sancar-Bas S, Kaptan E, Sengezer-Inceli M, Sezen A, Us H. Glycoconjugate histochemistry in the fungic stomach and small intestine of the frog (*Rana ridibunda*) IUFS J Biol. 2009; 68(2):93-104.

31. Scillitani G, Mentino D, Liquori GE, Ferri D. Histochemical characterization of the mucins of the alimentary tract of the grass snake, Natrix natrix (Colubridae). Tissue Cell. 2012 Oct;44(5):288-95. doi: 10.1016/j.tice.2012.04.006.

32. Becker DJ, Lowe JB. Fucose: biosynthesis and biological function in mammals. Glycobiology. 2003 Jul;13(7):41R-53R.

33. Ferri D, Liquori GE. Characterization of secretory cell glycoconjugates in the alimentary tract of the ruin lizard (Podarcis sicula campestris De Betta) by means of lectin histochemistry. Acta Histochem. 1992;93(1):341-9.

34. Costello EK, Gordon JI, Secor SM, Knight R. Postprandial remodeling of the gut microbiota in Burmese pythons. ISME J. 2010 Nov;4(11):1375-85. doi: 10.1038/ismej.2010.71.